

# Female Reproductive System

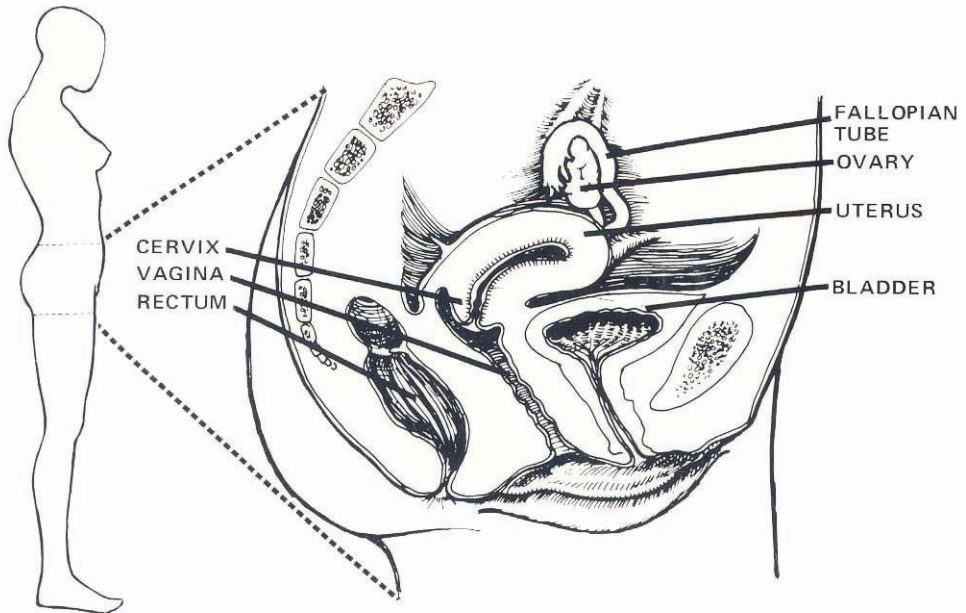
1



DEPARTMENT OF HEALTH AND HUMAN SERVICES  
Centers for Disease Control and Prevention  
Atlanta, Georgia, 30333



# FEMALE REPRODUCTIVE SYSTEM



# Male Reproductive System

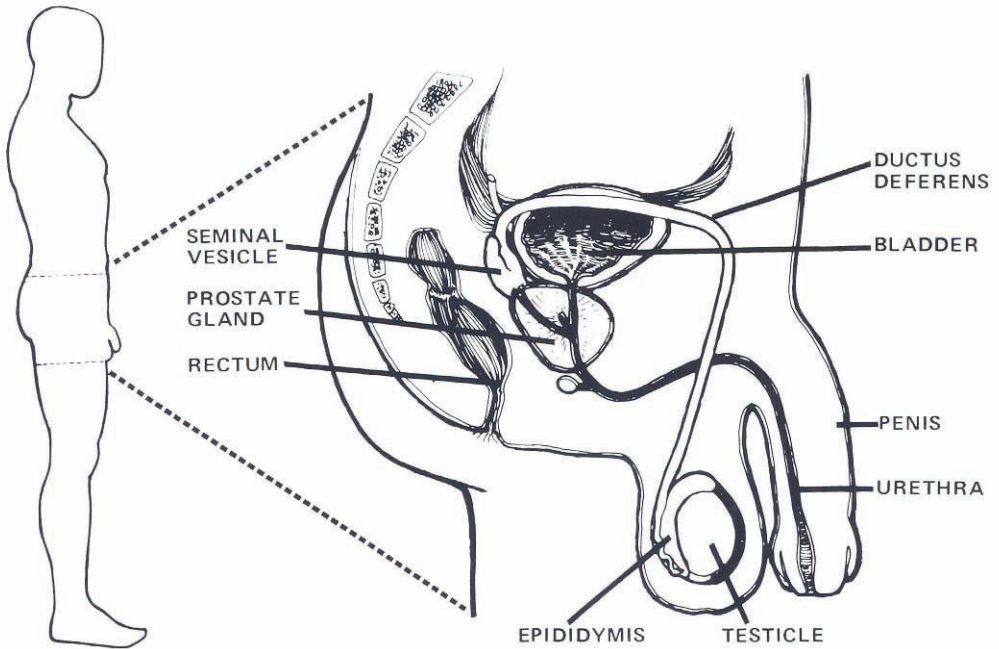
2



DEPARTMENT OF HEALTH AND HUMAN SERVICES  
Centers for Disease Control and Prevention  
Atlanta, Georgia, 30333



# MALE REPRODUCTIVE SYSTEM



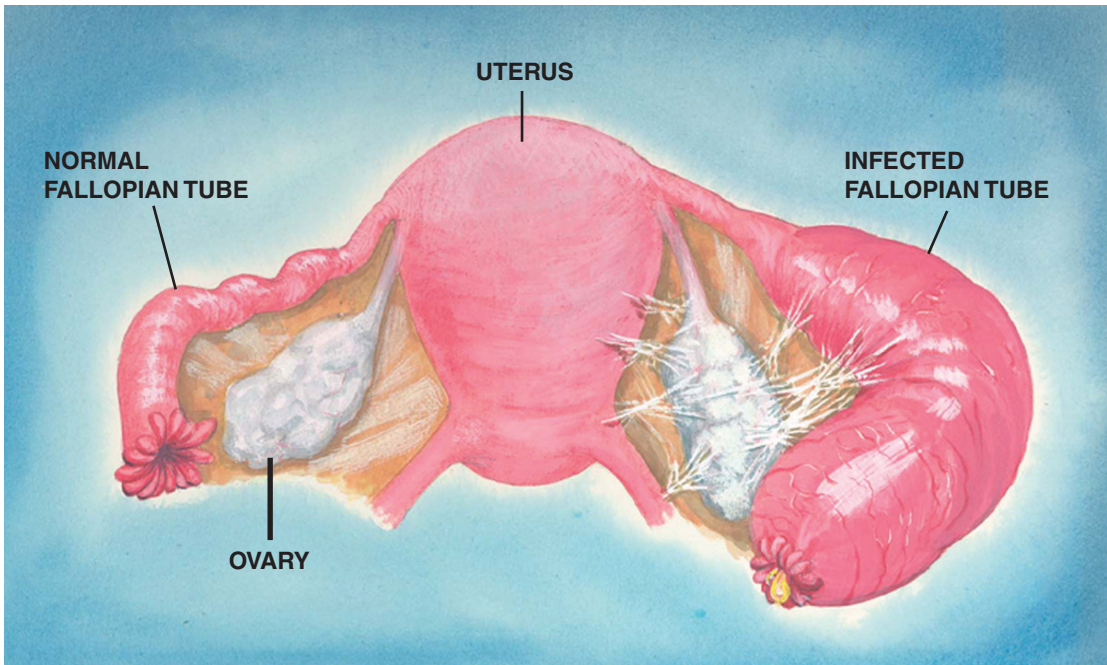
## Acute Salpingitis (PID)

3



DEPARTMENT OF HEALTH AND HUMAN SERVICES  
Centers for Disease Control and Prevention  
Atlanta, Georgia, 30333





## ACUTE SALPINGITIS (PID)

## Penile discharge, gonorrhea

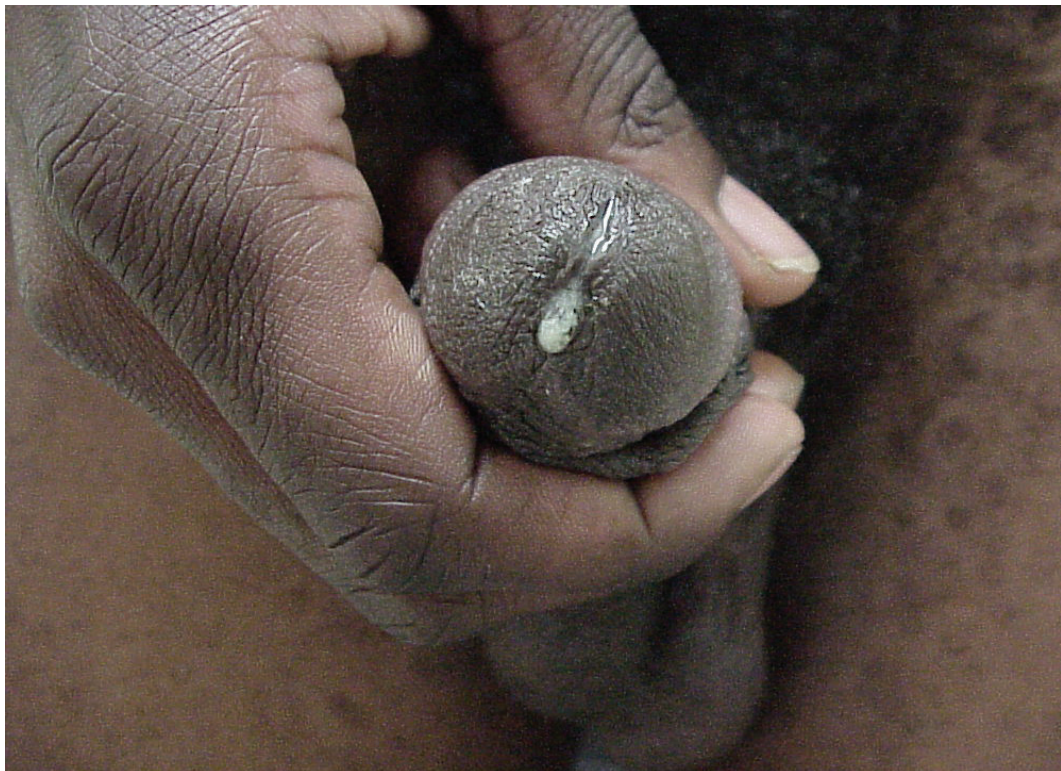Source: Cincinnati STD/HIV Prevention Training Center

4



DEPARTMENT OF HEALTH AND HUMAN SERVICES  
Centers for Disease Control and Prevention  
Atlanta, Georgia, 30333





## Penile chancre, shaft

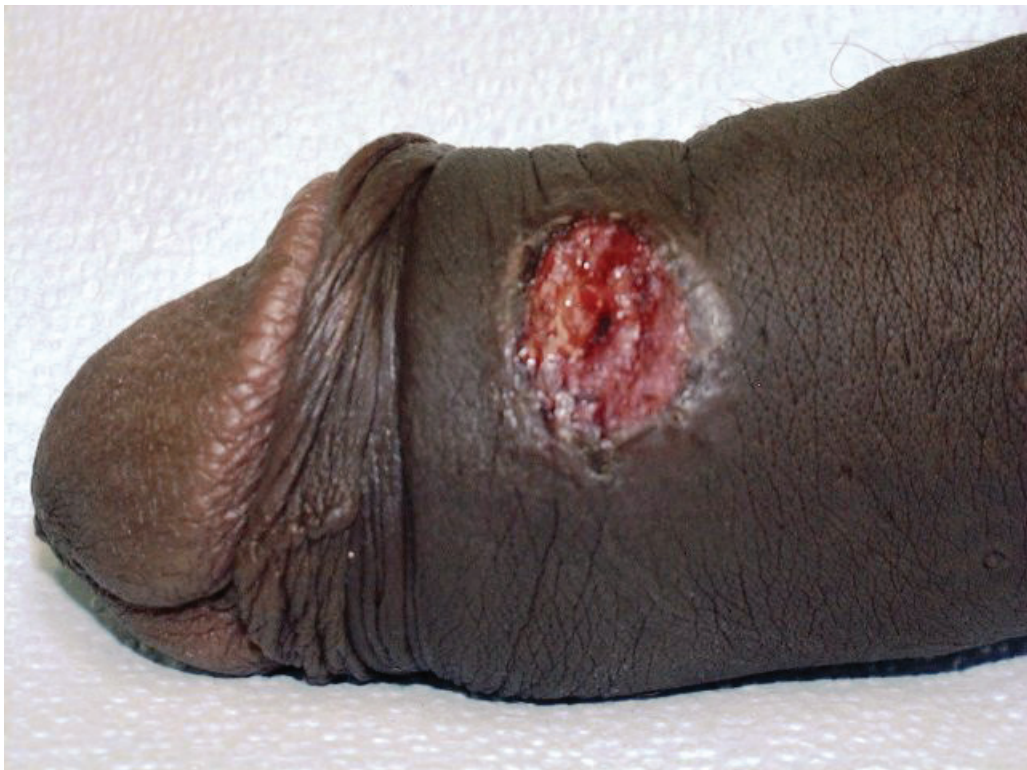Source: Dr. John Toney, Southeast STD/HIV Prevention Training Center

5



DEPARTMENT OF HEALTH AND HUMAN SERVICES  
Centers for Disease Control and Prevention  
Atlanta, Georgia, 30333





## Penile chancre, underside of glans

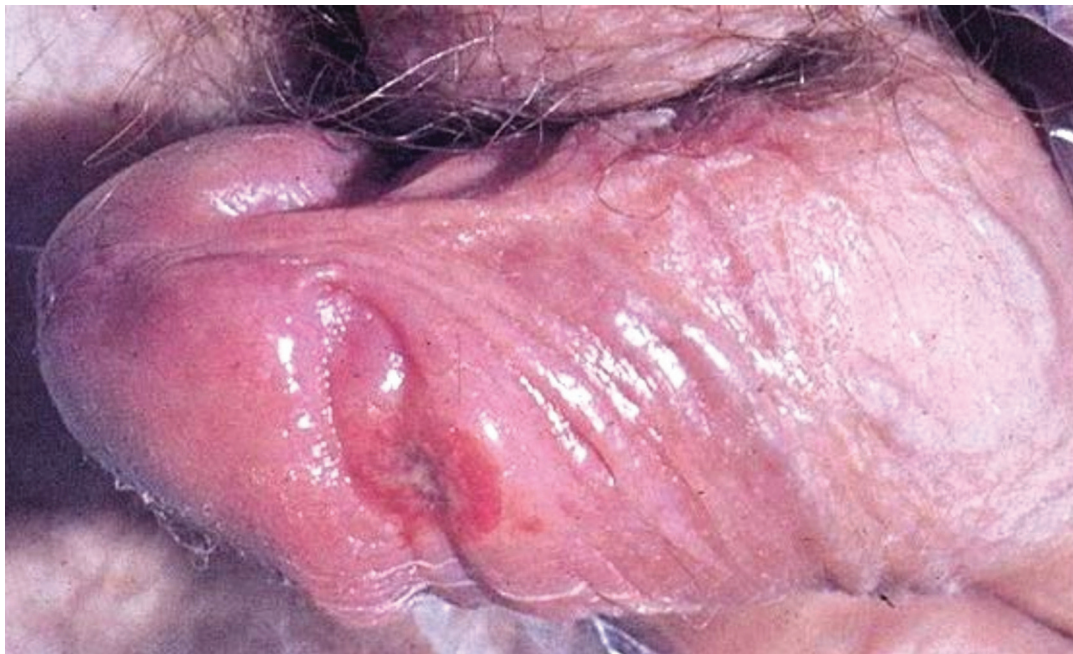Source: Public Health Agency of Canada

6



DEPARTMENT OF HEALTH AND HUMAN SERVICES  
Centers for Disease Control and Prevention  
Atlanta, Georgia, 30333





## Perianal chancre

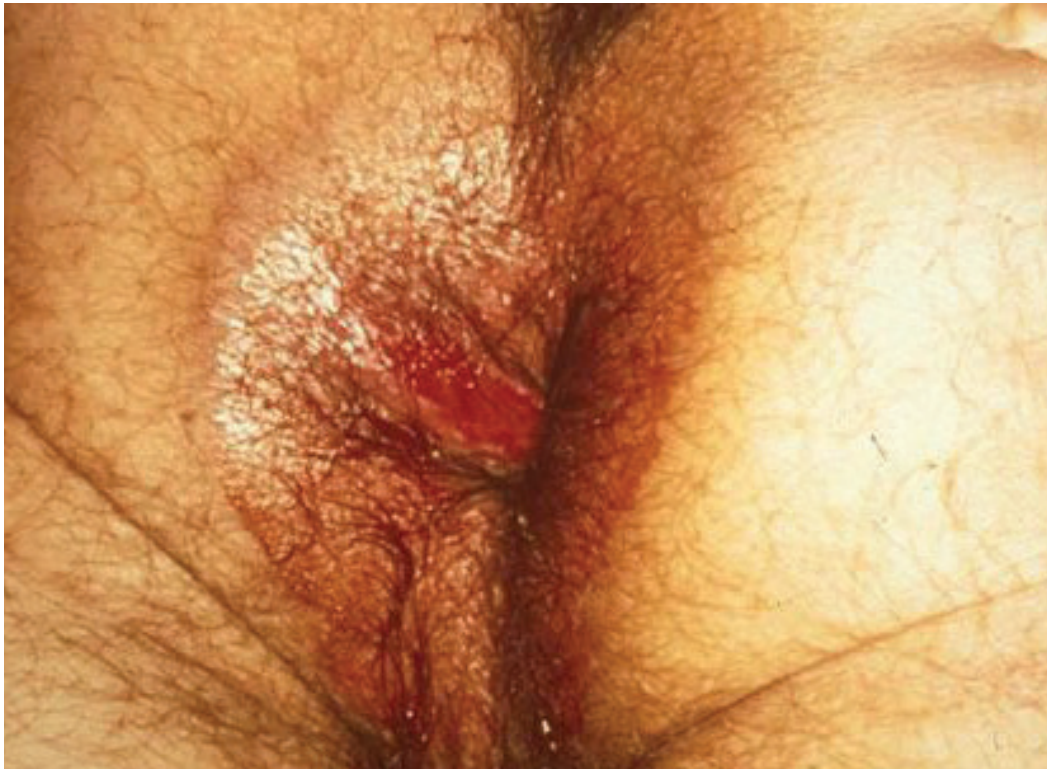Source: Negusse Ocbamichael, Seattle STD/HIV Prevention Training Center

7



DEPARTMENT OF HEALTH AND HUMAN SERVICES  
Centers for Disease Control Prevention  
Atlanta, Georgia, 30333





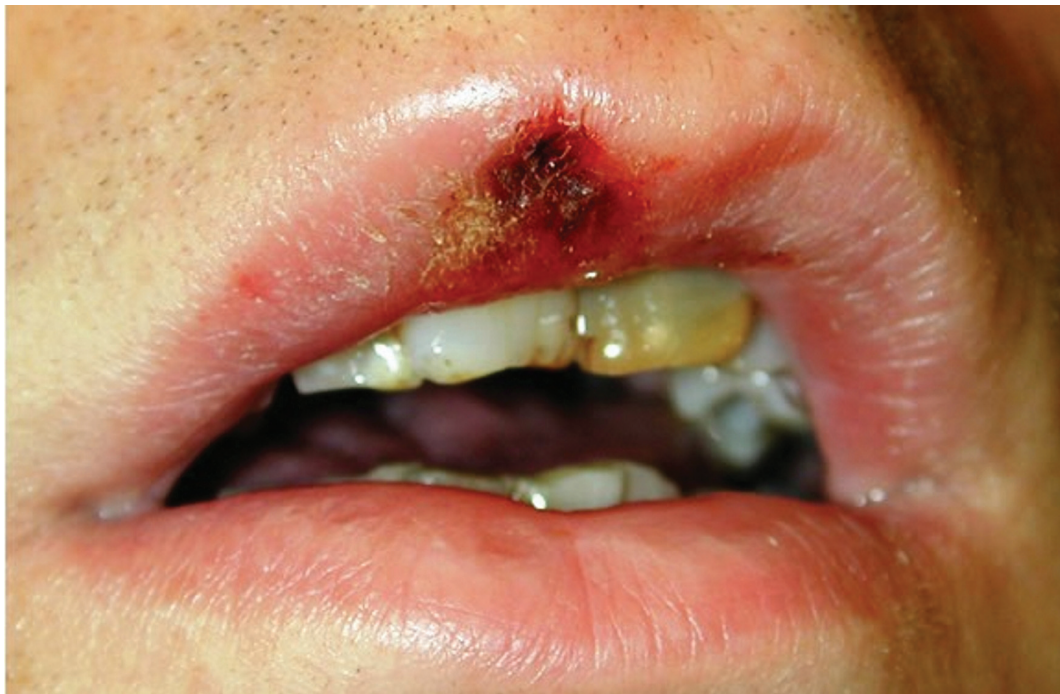Oral chancre, upper lip  
Source: Public Health Agency of Canada

8



DEPARTMENT OF HEALTH AND HUMAN SERVICES  
Centers for Disease Control Prevention  
Atlanta, Georgia, 30333





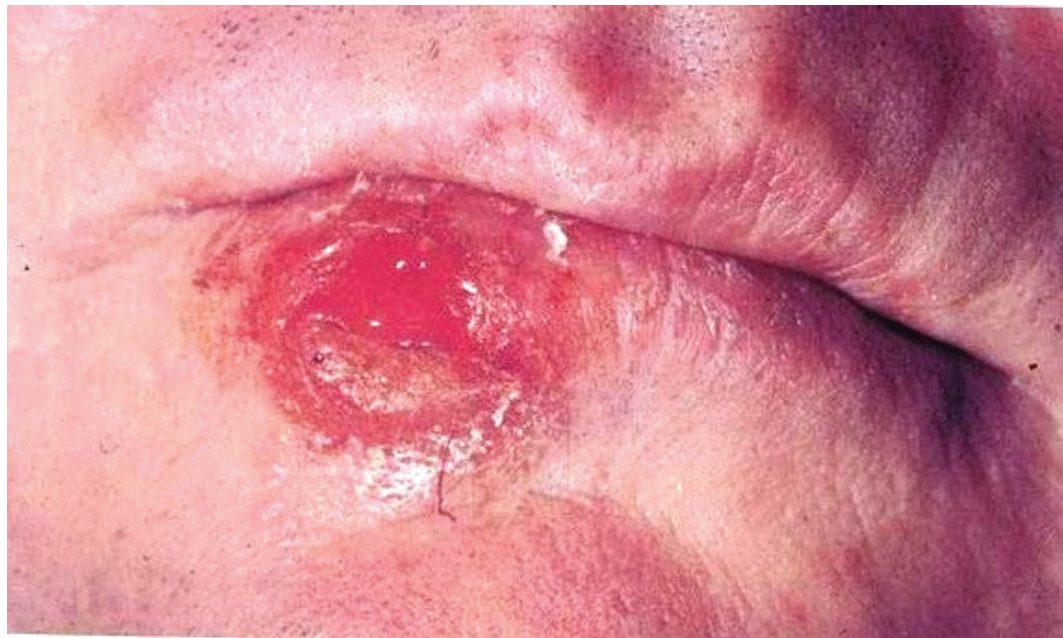Oral chancre, lower lip  
Source: Public Health Agency of Canada

9



DEPARTMENT OF HEALTH AND HUMAN SERVICES  
Centers for Disease Control Prevention  
Atlanta, Georgia, 30333





## Palmar and plantar rash

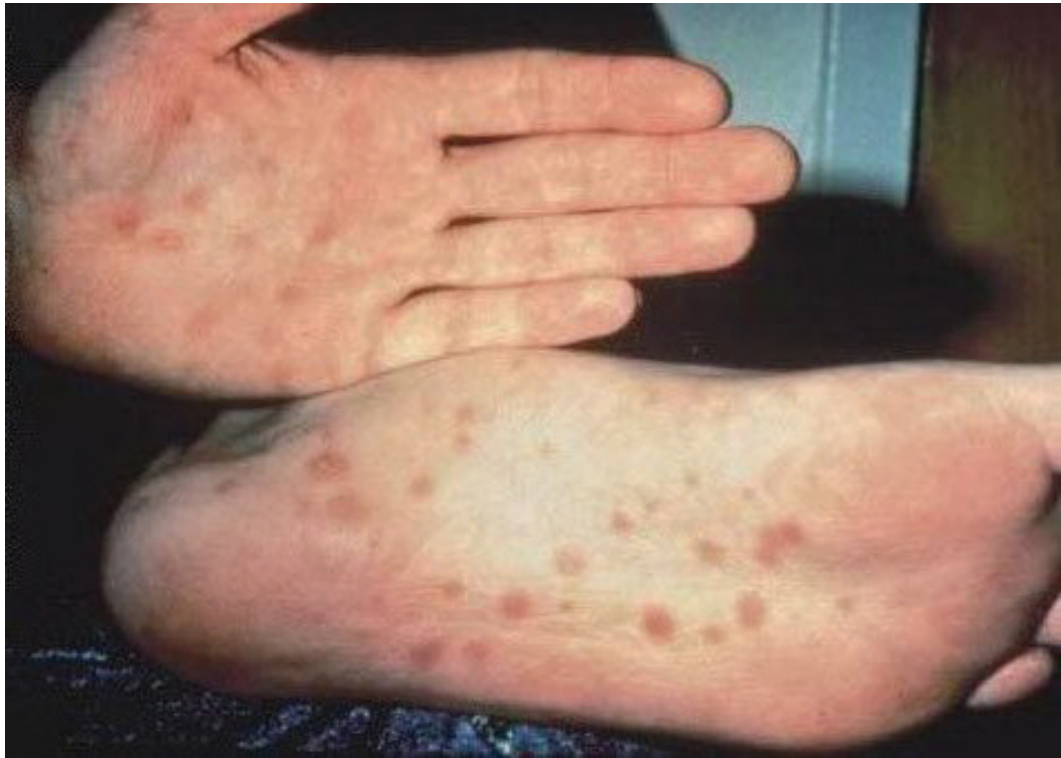Source: Connie Celum, Walter Stamm, Seattle STD/HIV Prevention Training Center

10



DEPARTMENT OF HEALTH AND HUMAN SERVICES  
Centers for Disease Control and Prevention  
Atlanta, Georgia, 30333





## Plantar rash

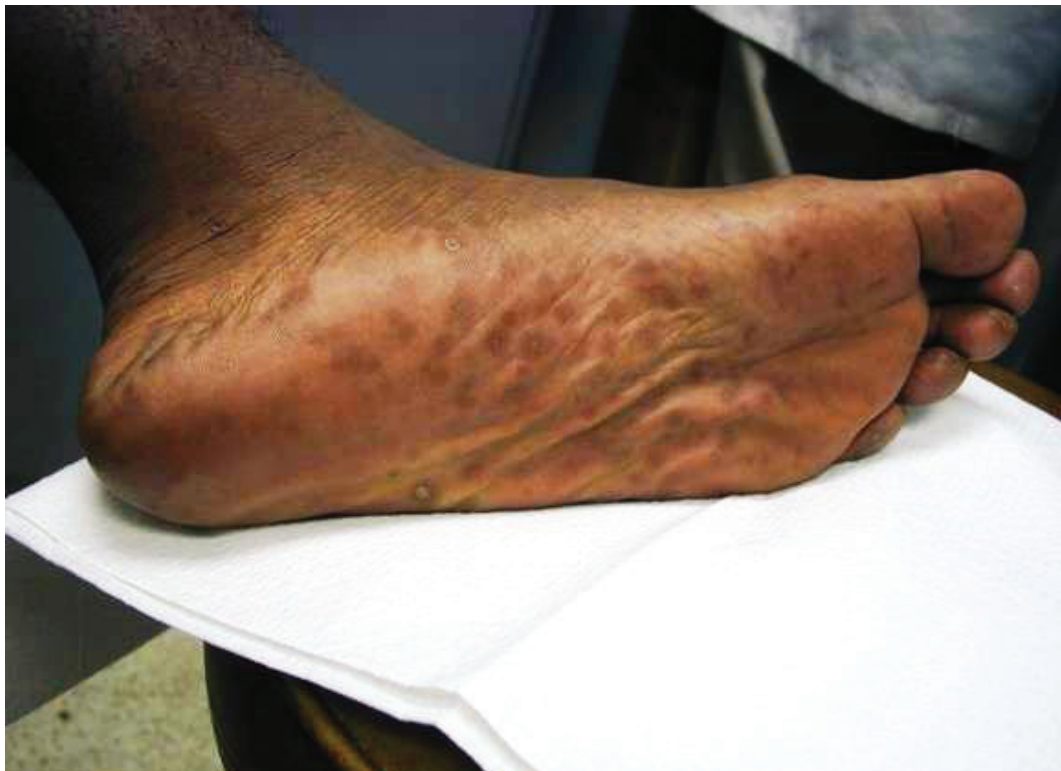Source: Dr. John Toney, Southeast STD/HIV Prevention Training Center

11



DEPARTMENT OF HEALTH AND HUMAN SERVICES  
Centers for Disease Control Prevention  
Atlanta, Georgia, 30333





## Palmar rash

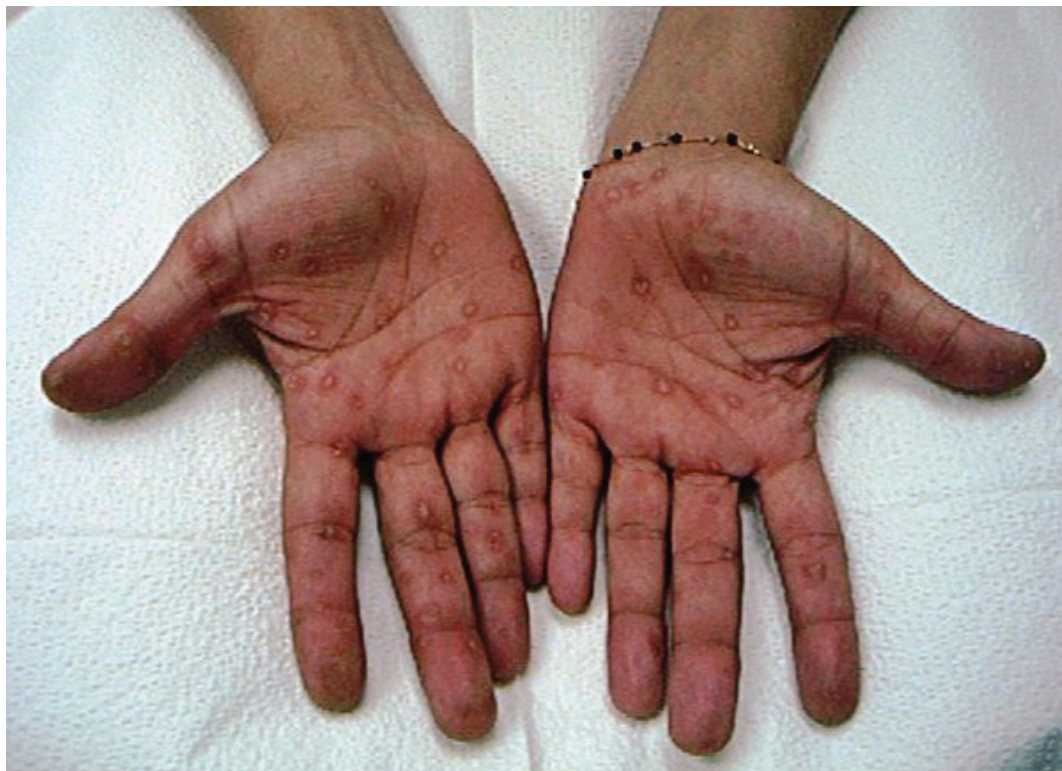Source: Dr. John Toney, Southeast STD/HIV Prevention Training Center

12



DEPARTMENT OF HEALTH AND HUMAN SERVICES  
Centers for Disease Control and Prevention  
Atlanta, Georgia, 30333





## Alopecia (1)

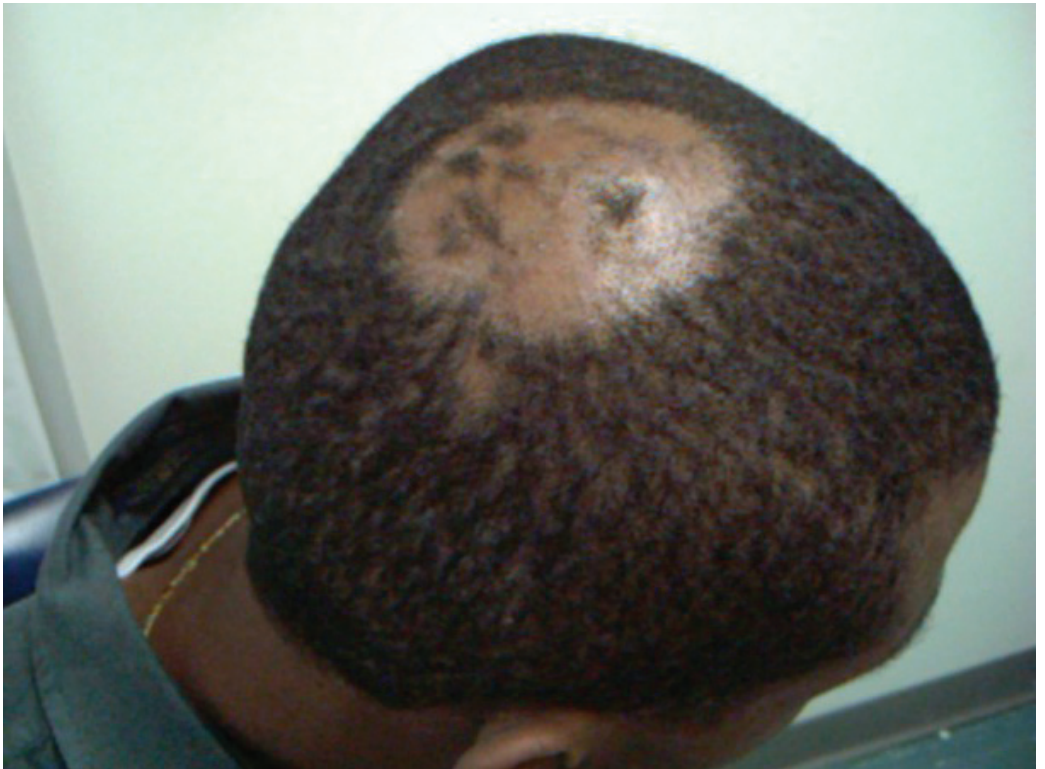Source: Dr. John Toney, Southeast STD/HIV Prevention Training Center

13



DEPARTMENT OF HEALTH AND HUMAN SERVICES  
Centers for Disease Control Prevention  
Atlanta, Georgia, 30333





## Alopecia (2)

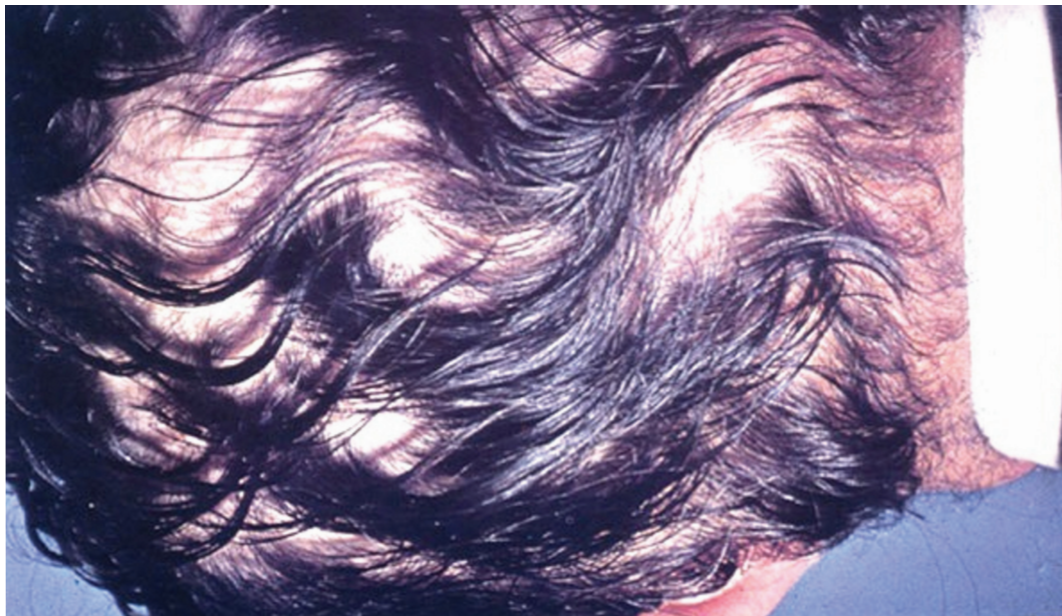Source: Public Health Agency of Canada

14



DEPARTMENT OF HEALTH AND HUMAN SERVICES  
Centers for Disease Control and Prevention  
Atlanta, Georgia, 30333





## Generalized body rash

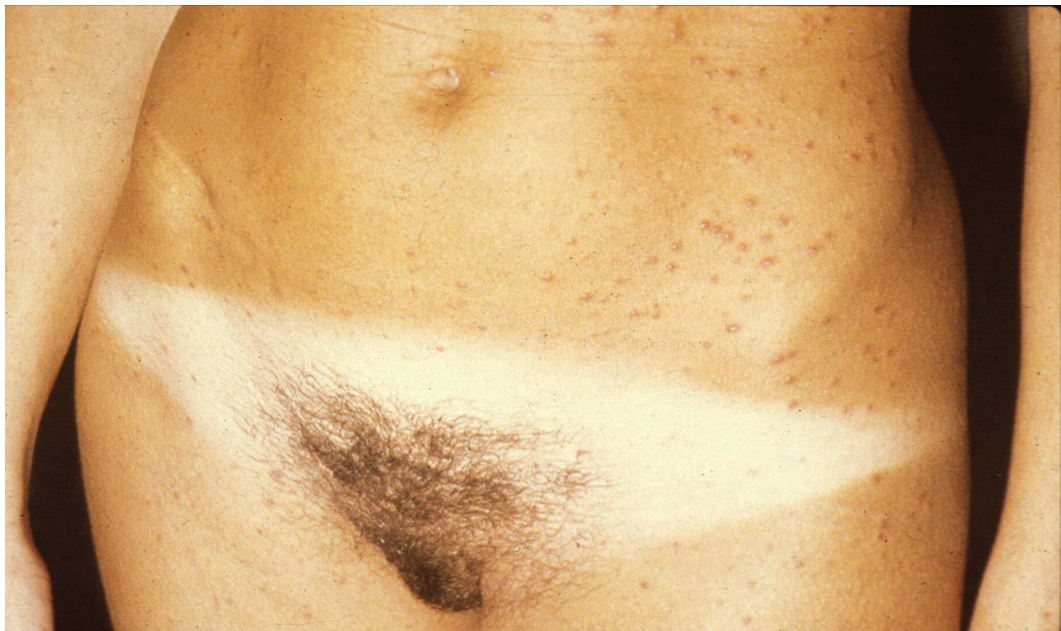
Source: Seattle STD/HIV Prevention Training Center

15



DEPARTMENT OF HEALTH AND HUMAN SERVICES  
Centers for Disease Control and Prevention  
Atlanta, Georgia, 30333





## Condylomata lata, labia

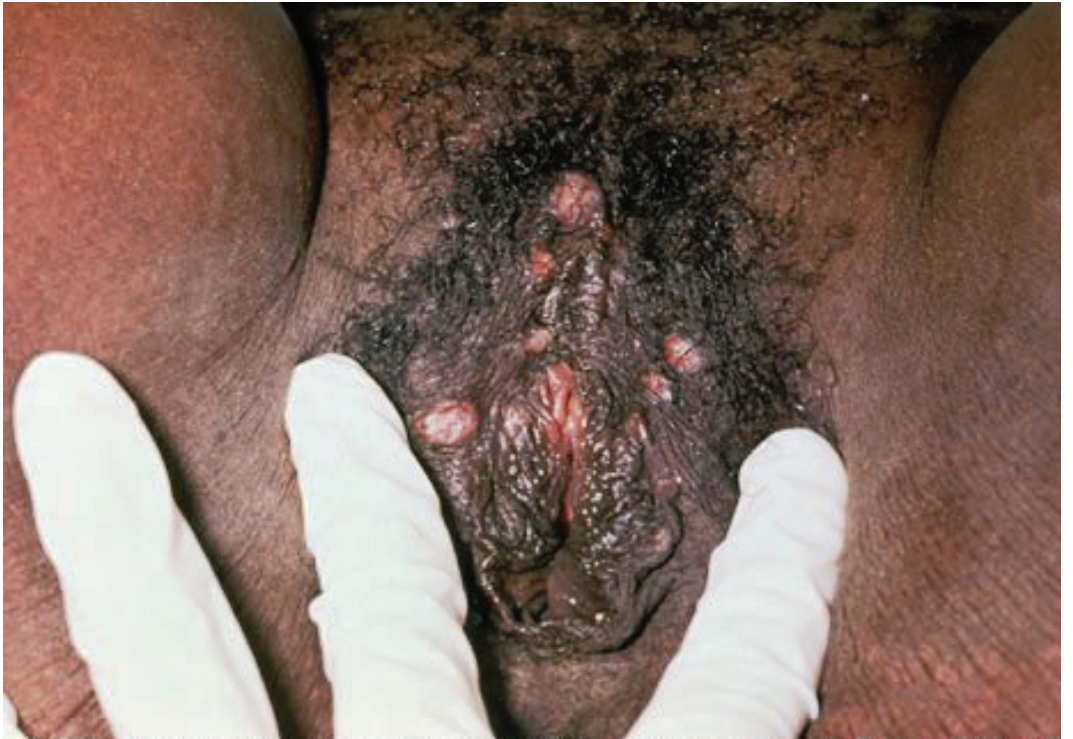Source: Connie Celum, Walter Stamm, Seattle STD/HIV Prevention Training Center

16



DEPARTMENT OF HEALTH AND HUMAN SERVICES  
Centers for Disease Control and Prevention  
Atlanta, Georgia, 30333





## Condylomata lata, penis

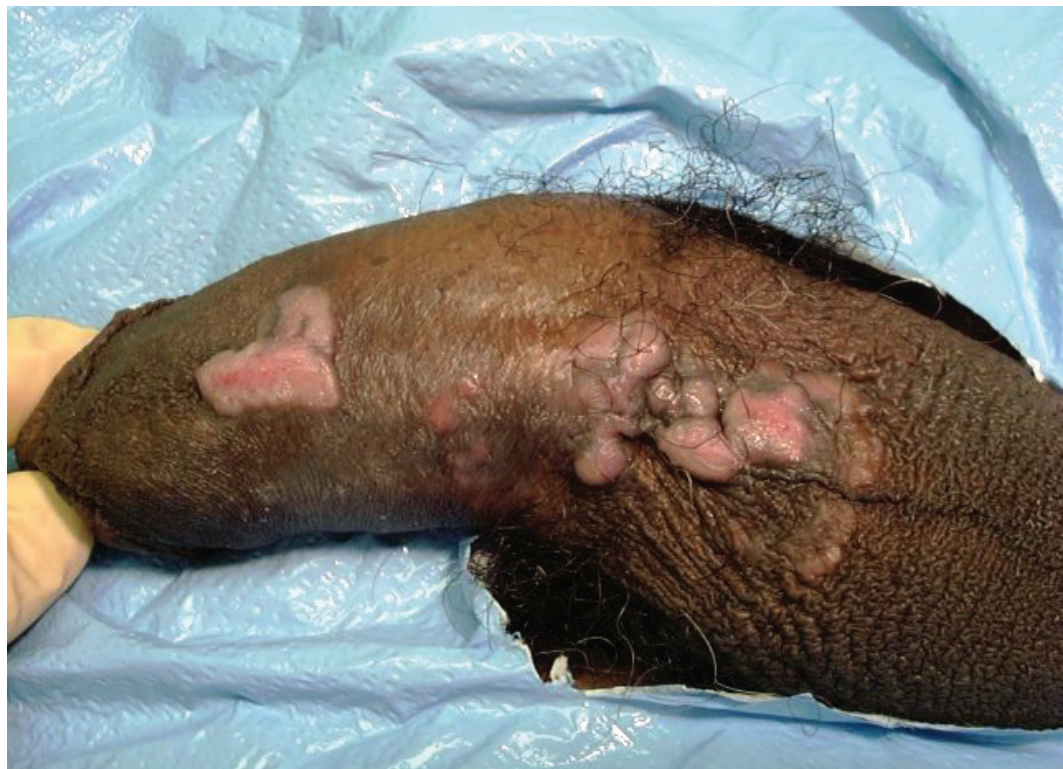Source: Dr. John Toney, Southeast STD/HIV Prevention Training Center

17



DEPARTMENT OF HEALTH AND HUMAN SERVICES  
Centers for Disease Control Prevention  
Atlanta, Georgia, 30333





## Mucous patches, oral

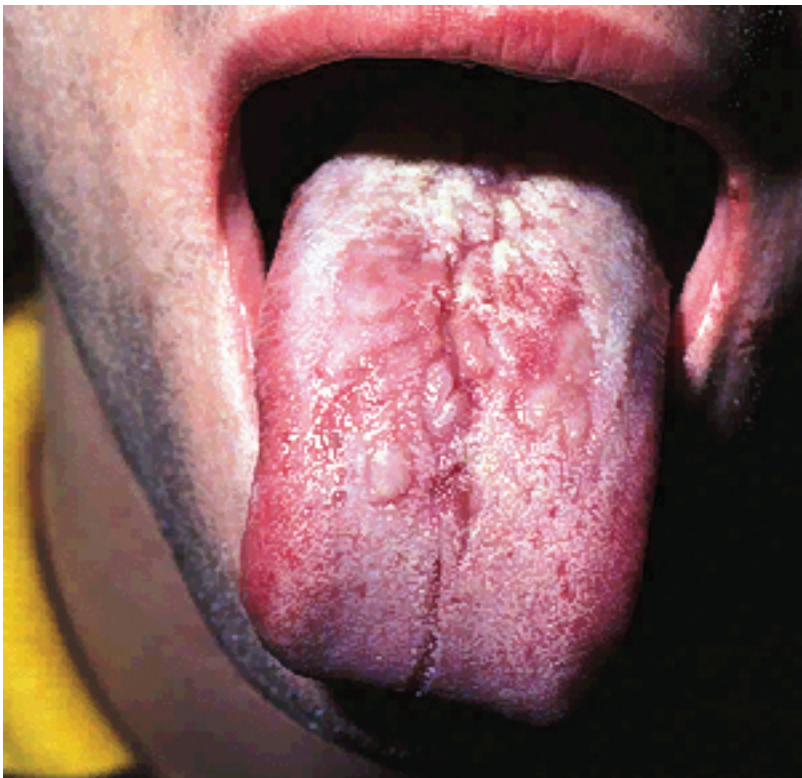Source: Seattle STD/HIV Prevention Training Center

18



DEPARTMENT OF HEALTH AND HUMAN SERVICES  
Centers for Disease Control Prevention  
Atlanta, Georgia, 30333





## Congenital syphilis exhibiting classic skin rash

Source: Ron Ballard, Centers for Disease Control and Prevention,  
Division of STD Prevention

19



DEPARTMENT OF HEALTH AND HUMAN SERVICES  
Centers for Disease Control and Prevention  
Atlanta, Georgia, 30333



